

**Tikrit University**  
**College of Medicine**  
**Department of Radiology**

**Introduction to**

# **GI Radiology**

**Dr. Omar M. Sultan**  
**MBChB, MSc (Rad), FEBR**

# Contrast Medium for Oral GI Studies

## Barium (Non-water soluble)

- Can cause severe peritonitis and fibrosis in perforation or leakage.
- Contraindicated in case of perforation or leakage, partial & complete obstruction, suspected aspiration.

## Gastrografin (Water Soluble)

- High osmolar , Gastrografin may cause the loss of a large amount of fluid into the intestines. High osmolarity make the gastrographin of therapeutic action in case of uncomplicated meconium ileus.
- Used in CT examination.

# Contrast Studies

- Esophagus
  - *Ba Swallow*
- Stomach
  - *Ba Meal*
- Small Bowel
  - *Ba Follow Through*
- Large bowel
  - *Ba Enema*

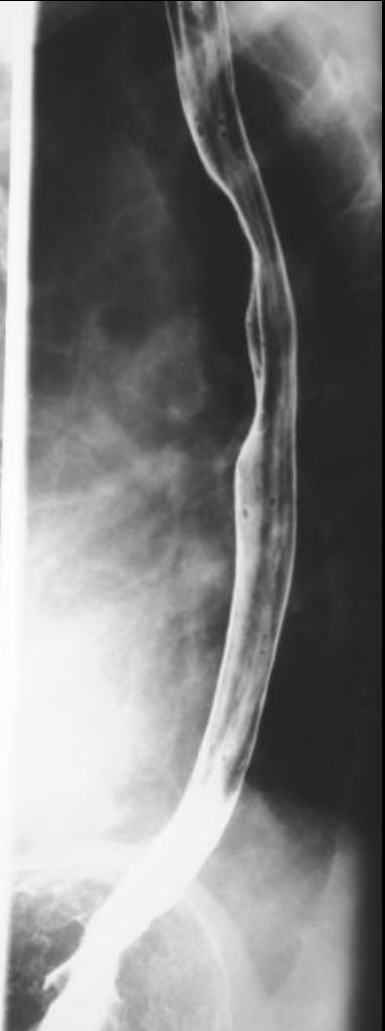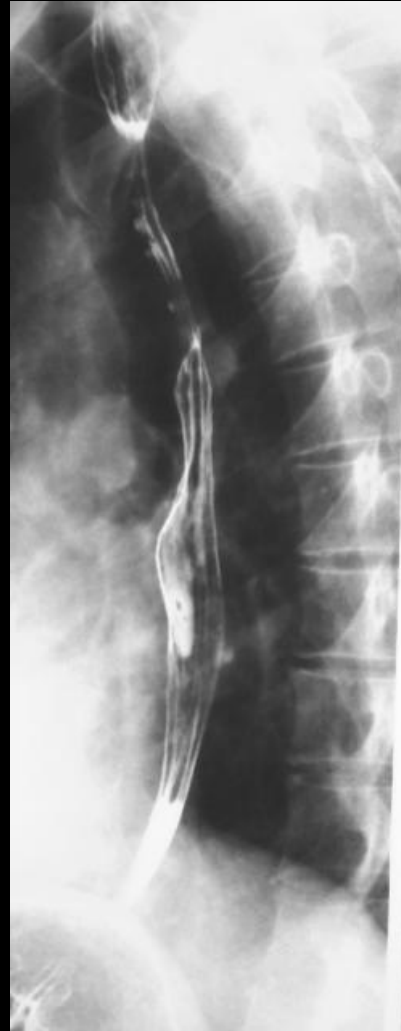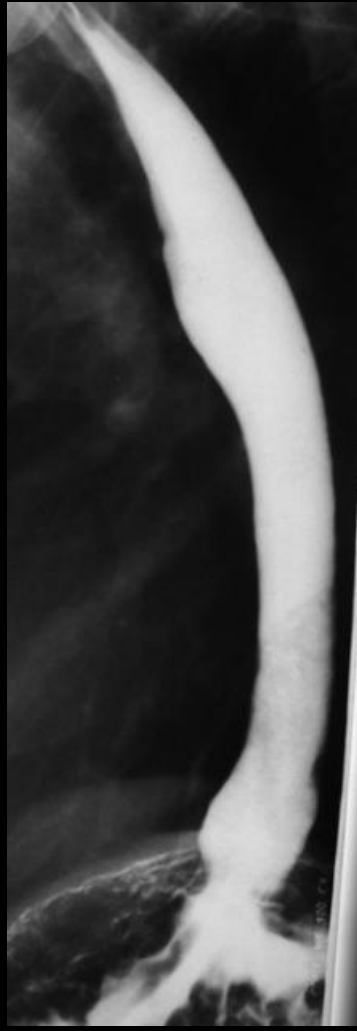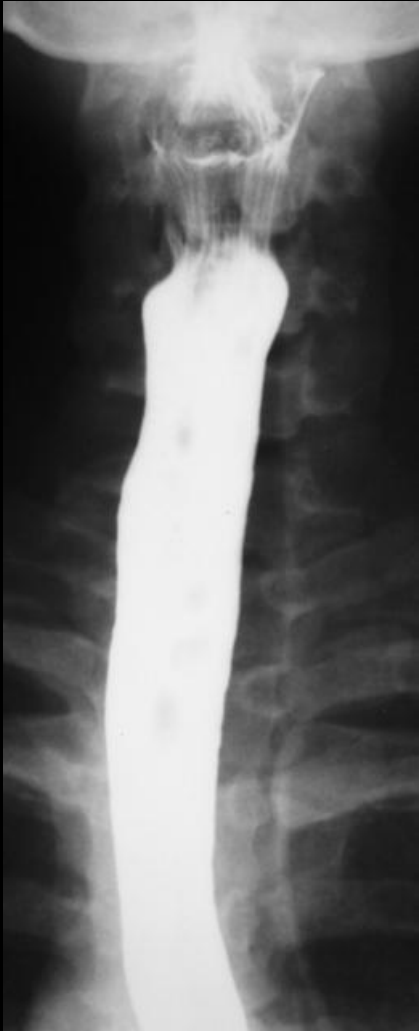# Ba Swallow

- Indications:

- Dysphagia
- Pain
- Gastro-Esophageal-Reflux Disease (GERD)
- Anemia
- Assessment of Hiatus hernia, Ulcer, Diverticulosis & Stricture.
- In case of suspected perforation, Gastrographin is used

- Contraindications

- Aspiration
- Perforation



# Barium Meal

## • Indications:

- Dyspepsia
- Upper abdominal mass
- Weight Loss
- Recurrent vomiting (gastric outlet obstruction)
- Gastrointestinal Hemorrhage.
- Peptic Ulcer, Diverticulosis .

## • Contraindications

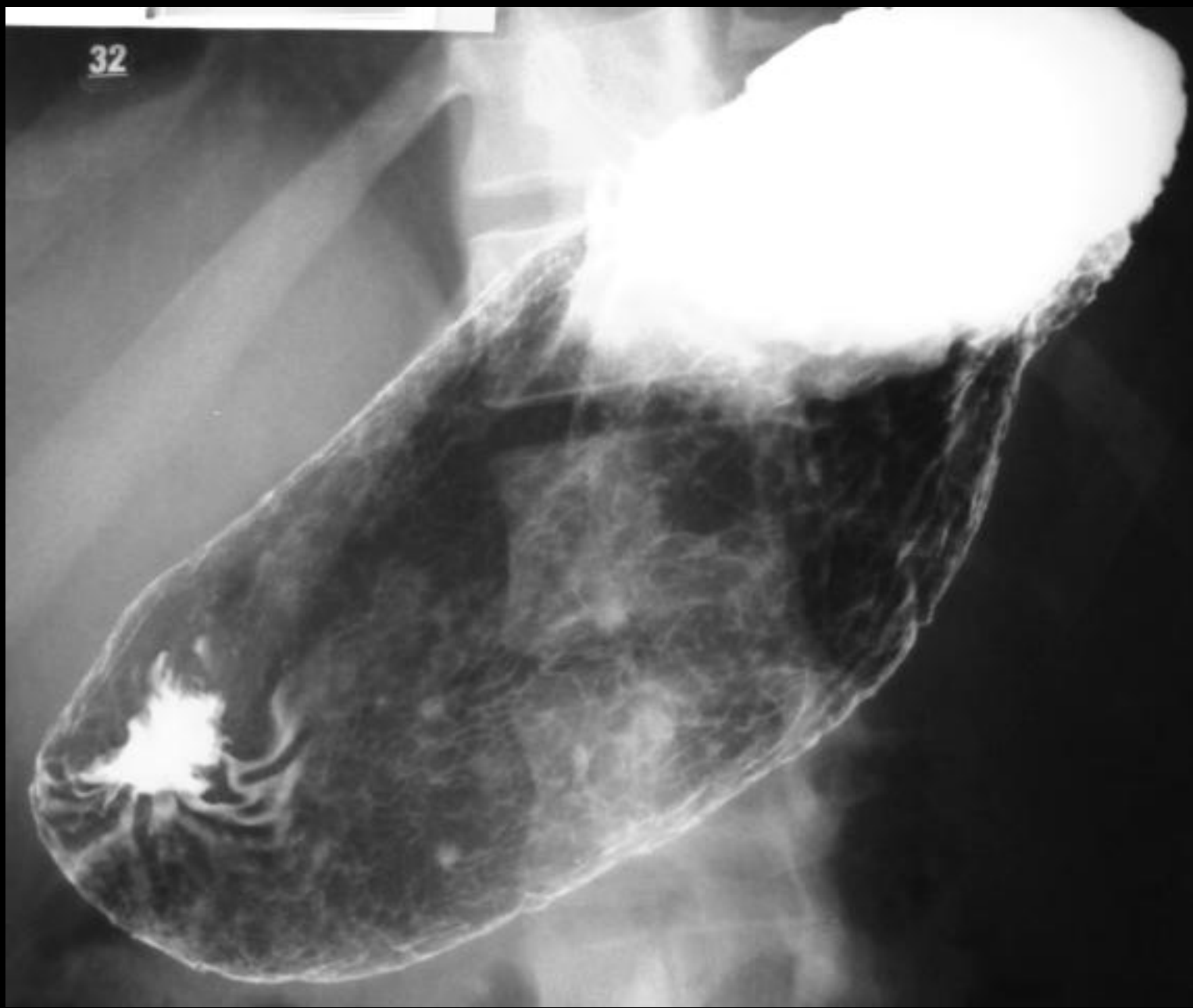- Complete large bowel obstruction
- Suspected perforation

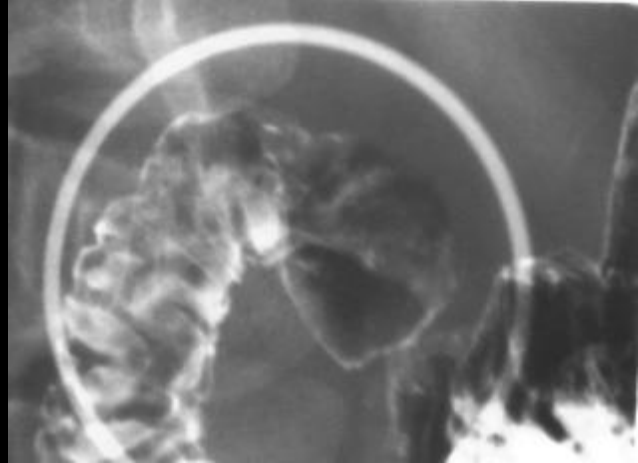
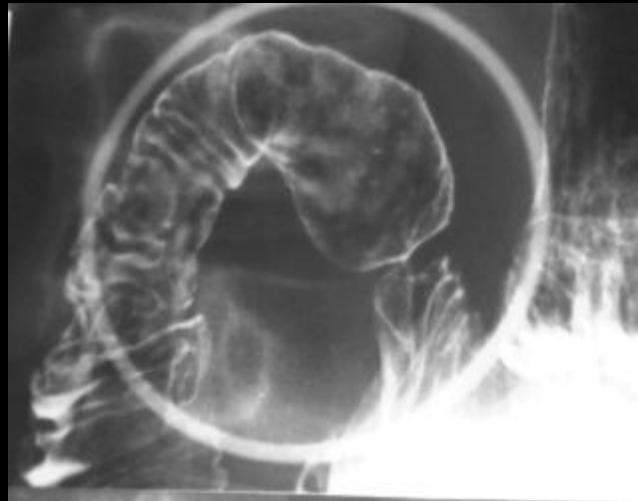
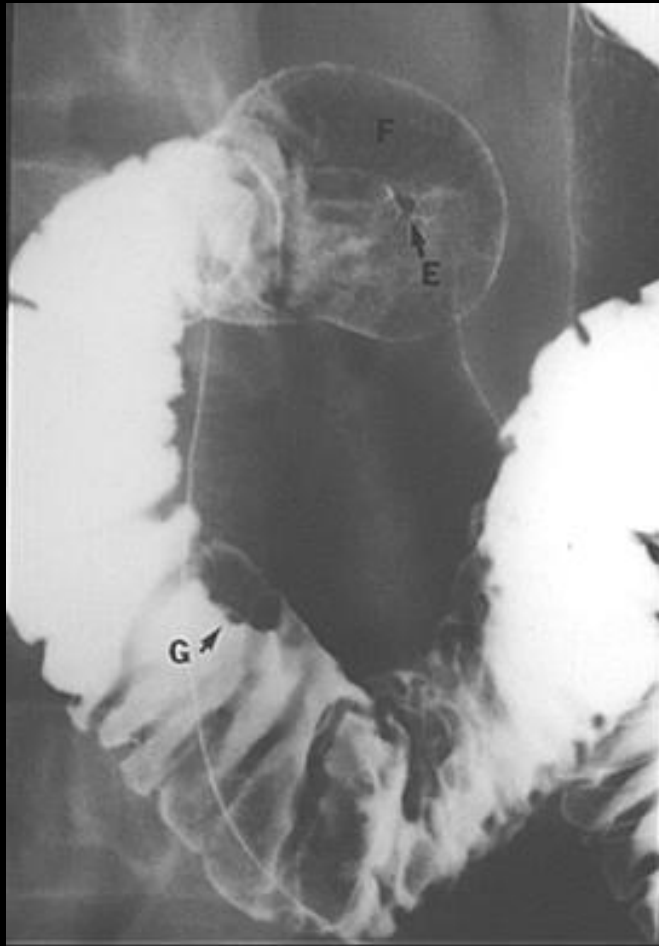
## • Patient preparation:

- NPO ---6 hrs
- No smoking– increases GI motility

In case of suspected perforation, Gastrographin is used

32







# Small Bowel Follow through

## Small bowel enema (Enteroclysis)

### • Indications

- Pain
- Diarrhoea
- Anemia/GI bleed
- Malabsorption
- Abdominal mass
- Assessment of stricture (site, nature & length)

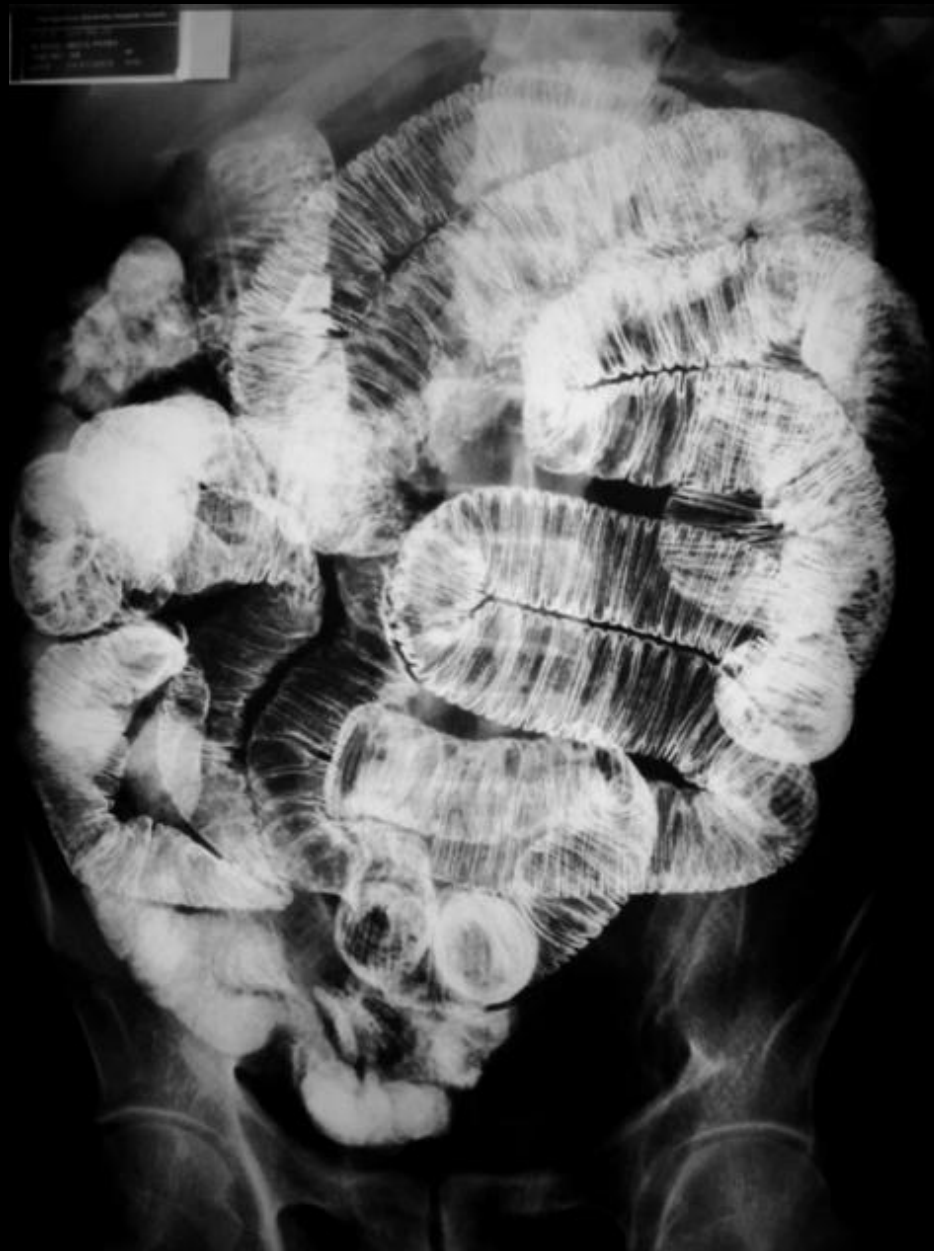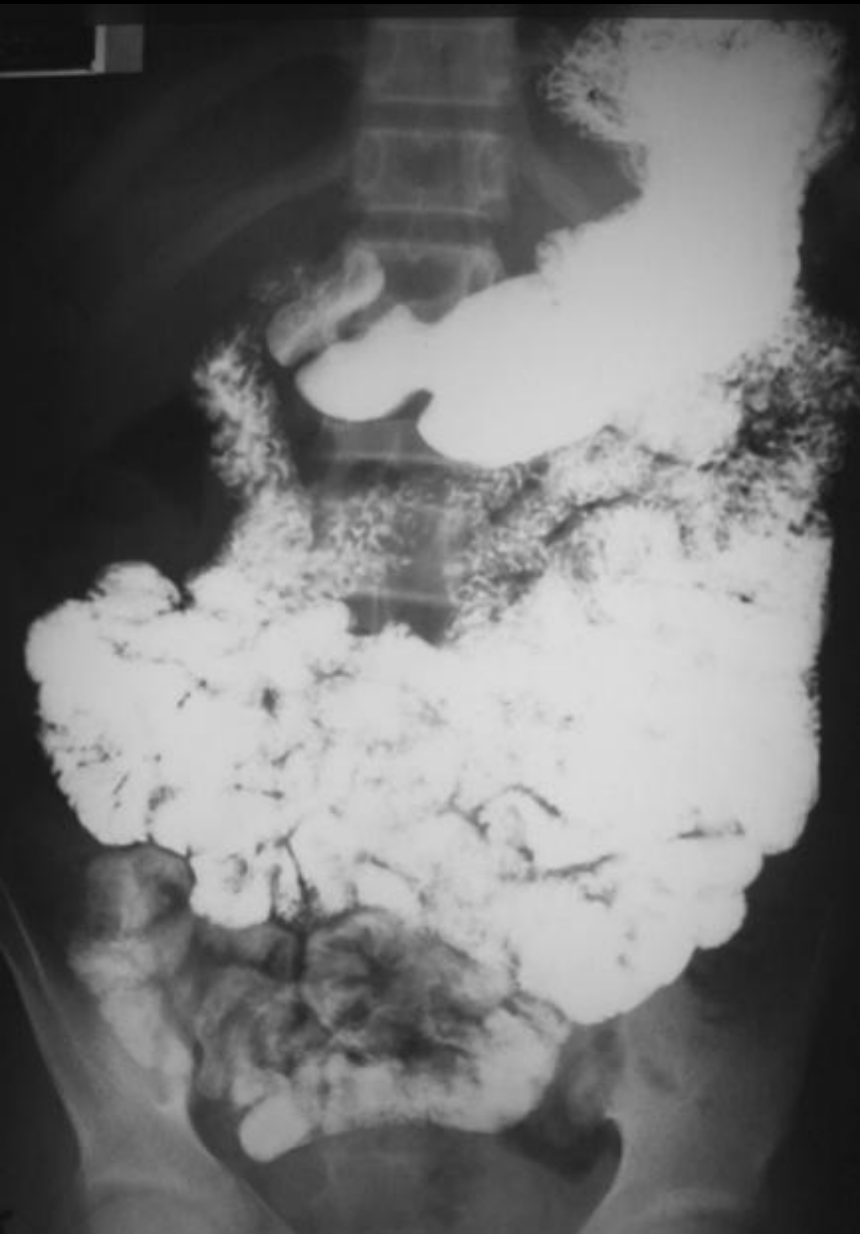
### • Contraindications

- Bowel obstruction

### • Patient Preparation

- Low residue diet
- Bowel Prep: Dulcolax -2-4 Tab

# Small Bowel follow through VS Small bowel enema



# Barium Enema

## • Indications

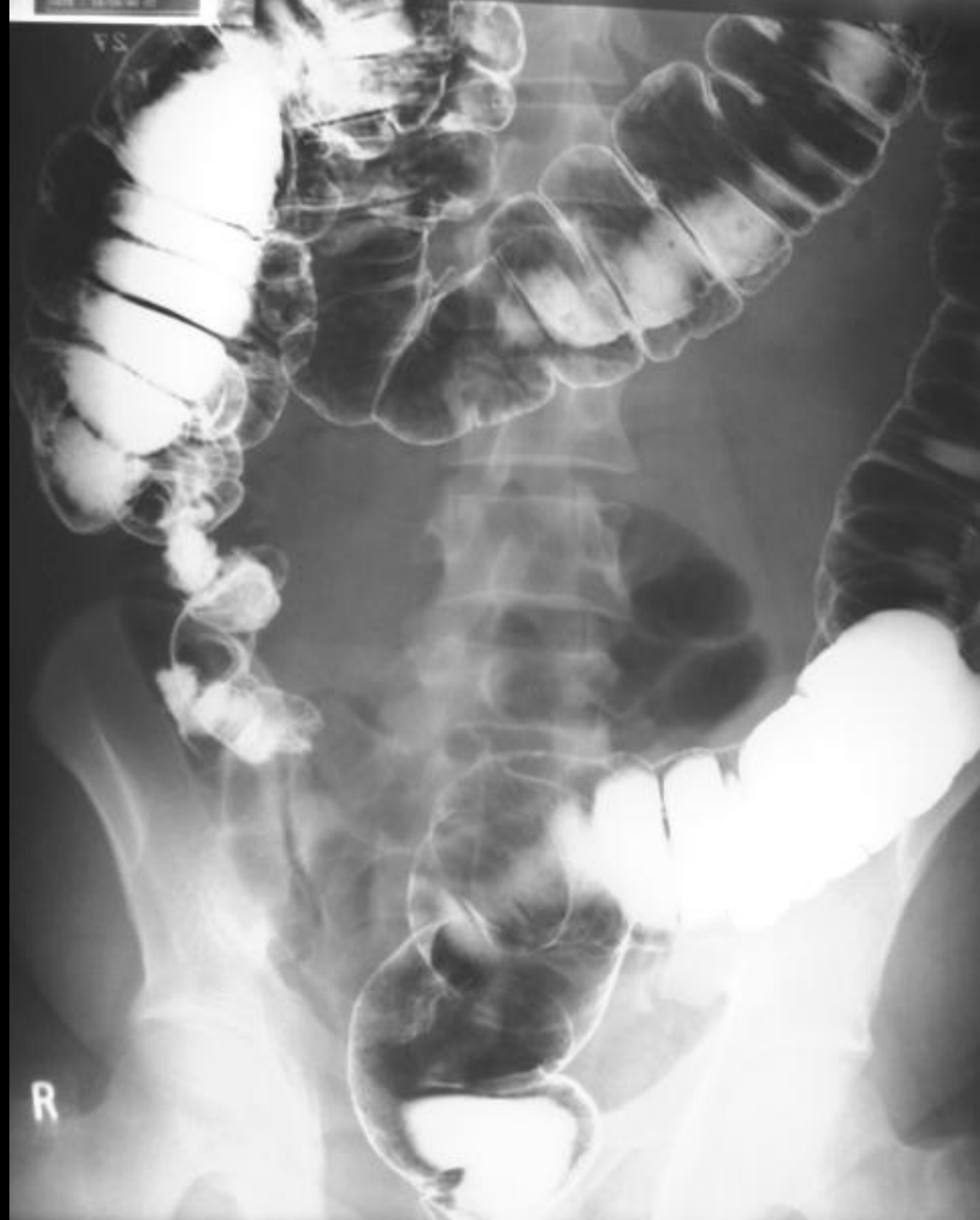- Change in bowel habits
- Pain
- Mass
- Melaena / Anemia
- Single contrast in case of Obstruction & Intussusceptions to assess the level, length & nature of obstruction and may have a therapeutic action with caution of perforation.

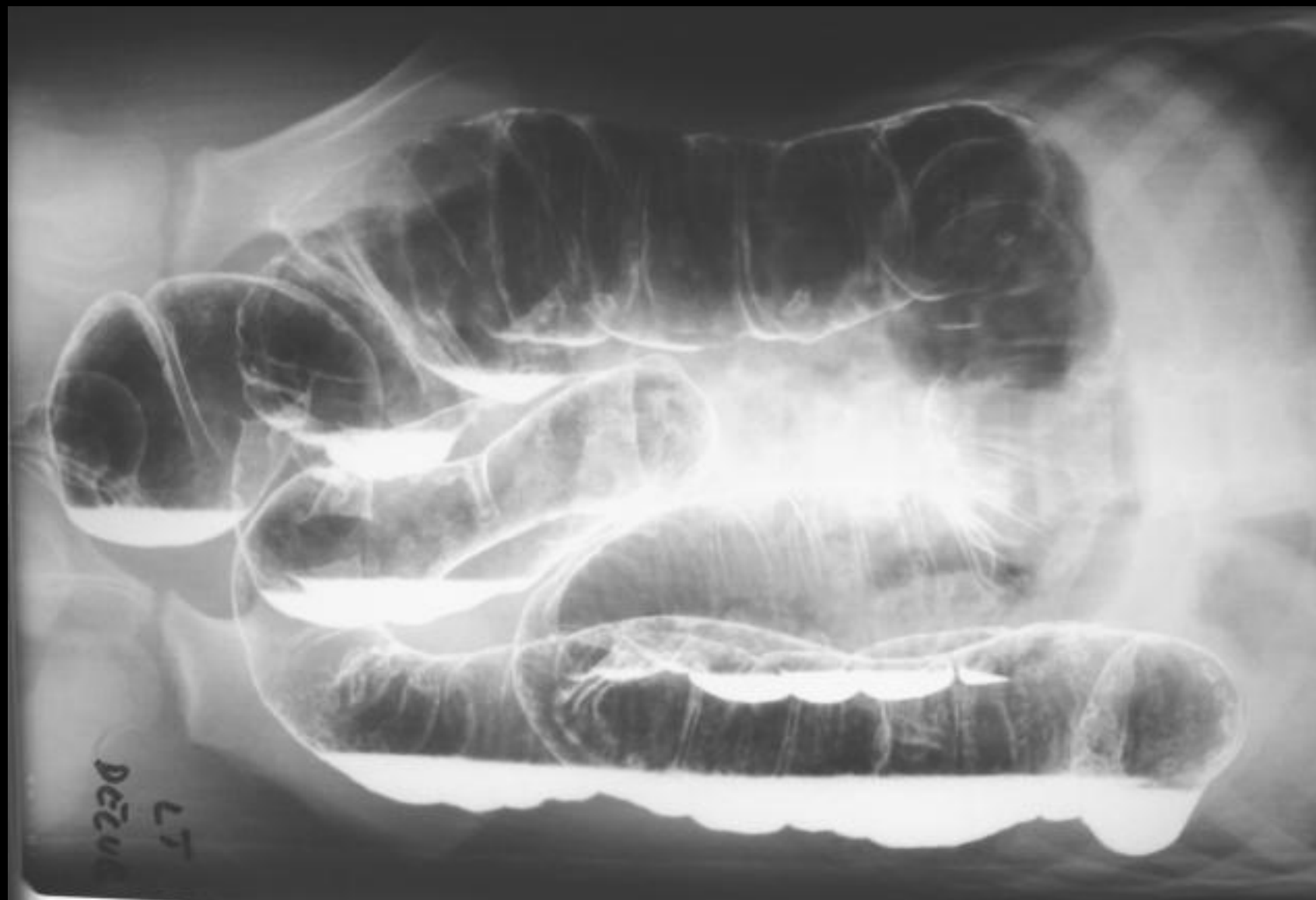
## • Contraindications

- Rectal biopsy—5 days
- Toxic megacolon
- Pseudomembranous colitis

## • Preparation: (2 days)

- Low residue diet
- Bowel prep (Dulcolax – 4 Tab)





LT  
DECU

Thank  
You!

سبحانك اللهم و بحمدك  
اشهد ان لا اله الا انت  
استغفرك و اتوب اليك